PROCEEDINGS OF SPIE

SPIEDigitalLibrary.org/conference-proceedings-of-spie

Combined laser therapy for the treatment of psoriasis

Shnaider, Dmitry, Bakulev, Andrey, Moskvin, Sergey, Nechaeva, Olga, Ushakova, Olga

Dmitry A. Shnaider, Andrey L. Bakulev, Sergey V. Moskvin, Olga V. Nechaeva, Olga V. Ushakova, "Combined laser therapy for the treatment of psoriasis," Proc. SPIE 11845, Saratov Fall Meeting 2020: Optical and Nanotechnologies for Biology and Medicine, 118450Y (4 May 2021); doi: 10.1117/12.2588684

SPIE.

Event: Saratov Fall Meeting 2020, 2020, Saratov, Russian Federation

Combined laser therapy for the treatment of psoriasis

Dmitry A. Shnaider[a], Andrey L. Bakulev[a], Sergey V. Moskvin[b], Olga V. Nechaeva[c], Olga V. Ushakova[c]
[a]Saratov State Medical University, 112 Bolshaya Kazachia streat, Saratov, Russia; [b]Skobelkin State Scientific Center of Laser Medicine FMBA, 40 Studencheskaya streat, Moscow, Russia; [c]Saratov State Technical University, 77 Politechnicheskaya street, Saratov, Russia

Keywords: psoriasis, laser therapy, intravenous laser blood irradiation.

ABSTRACT

The aim of the study was to assess the effectiveness of the original treatment of patients with psoriasis, including VLOK-525 and the local impact of pulsed IR NEELIE. Under the supervision of 264 patients with widespread forms of psoriasis in progresive stage (163 men and 101 women) between the ages of 24 to 63 years old (average age - 41 years), being diagnosted with the disease from 1 to 30 years ago. In the main group the complex treatment included the original laser methods apparatus «LAZMIK VLOK», with the laser head emit KL-VLOK-525-20 for intravenous laser blood irradiation and ML-635-40 for external impact. It was shown that combined laser therapy of patients with a moderate form of psoriasis (10 <PASI<50), including a local effect on psoriatic elements by pulsed red light LIL (635 nm) with a power of 40 W with a pulse repetition rate of up to 10 Hz OOO-VLOK-667 allows effectively the cease of inflammatory changes and lead to a reduction in erythema, infiltration and exfoliation.

1. INTRODUCTION

The primary initiating mechanism of the (biological) therapeutic action of low-intensity laser radiation (LILR) is the thermodynamic stimulation processes of Ca 2+ - at the cellular level and at the level of the nervous system in general. LILR has an effect on the activation of the dopaminergic synapses of the central nervous system and the catecholaminergic synapses of the sympathetic branch of the autonomic nervous system with simultaneous suppression of excessive proliferation of keratinocytes[1].

In psoriasis, laser therapy is effective, based on a combination of unidirectional effects at various levels of physiological regulation and the formation of conditions for the normalization of disturbances in the regulation of the keratinocyte cell cycle. At the same time, the spectral-energy parameters of the technique should be limited in terms of the maximum permissible values[2-5]. Previously proposed laser exposure schemes (methods) did not meet this requirement and, as a result, did not demonstrate sufficient effectiveness. Another reason for this is the lack of power of the previously widely used helium-neon (GNL) and pulsed infrared (IR) lasers[4].

Rakcheev A. P. et al. was one of the first to apply the local effect of LIL on lesions in psoriasis (at a wave - 633 nm, power - 12 mW, the area of the light spot - 10-20 cm^2, exposure time - 5 min, the course - 15-20 sessions). However, a direct correlation between the normalization of biochemical (kinin-kallikrein system and sialic acids) and immunological indices with a clinical picture was not revealed[6].

Filippov N. E. recommends the use of pulsed infrared lenses in the complex treatment of patients with psoriasis, not only on the pathological skin focus, but also on the nose and tonsils area (the total time of the procedure is not more than 20 min, and the course -15-20 daily sessions)[7]. It is shown that, after laser illumination, pulsed LILR IR (power - 5-7 W, frequency 80 Hz, 10 sessions for 10 min), there is a more rapid regression of rashes on the background of normalization of various parameters of lipid peroxidation.

To increase the effectiveness of laser therapy, including patients with psoriasis, in addition to local effects on the focus, a method of non-invasive (percutaneous) laser blood clotting (NLOK) was proposed, in which a more powerful GNL (25 mW) and a special device for providing optimal laser input energy into the skin[8].

Saratov Fall Meeting 2020: Optical and Nano-Technologies for Biology and Medicine, edited by Valery V. Tuchin, Elina A. Genina, Proc. of SPIE Vol. 11845, 118450Y · © 2021 SPIE
CCC code: 1605-7422/21/$21 · doi: 10.1117/12.2588684

Close to the technical characteristics of lasers (at a wavelength of 628 nm, an average power of 0.5 W, a puised power of 10,000 W, a pulse duration of 10 ns, a frequency of 10,000 Hz) were used to treat psoriasis patients (the technique of supernumerary laser blood clotting (NLOK), exposure - 10 minutes, for the course - 10 sessions every other day)[3]. However, some parameters of the technique, particularly the selected exposure, did not provide it with the necessary efficiency.

Intravenous laser blood coverage for the treatment of patients with arthropathic psoriasis was one of the first to apply by Vil'shonkov A. I., who has developed an original technique for this purpose, providing for a gradual increase from session to session the power of radiation from 175 to 195 subthreshold maximal therapeutic (A = 633 nm , 25 mW)[9]. The normalizing effect of laser therapy on the level of cholesterol and phospholipids, the activity of antioxidant enzymes were shown.

Novakovsky A. L.et al proposed a laser combination therapy for psoriasis patients, conducted on the background of drug treatment. First, the psoriatic elements are illuminated with a helium-cadmium laser (at a wavelength of 441 nm, power density is 150-180 mW I cm 2, exposure is up to 7-10 min), then after an 1-minute pause these elements are irradiated with a heliumneon laser A = 633 nm, 150 mW / cm 2 at the same exposure)[10]. After external laser therapy, the VLOK is performed (A = 633 nm, power -1 mW, exposure - 30 min). The course consists of 10 daily procedures.

Nedosekova N. G., showed that with mild-severe forms of psoriasis, combined treatment, including VLOK (A = 633 nm) and laser puncture, is the most effective[11]. Clinical recovery or significant improvement was achieved in 91.9% of patients. Worse results of treatment regardless of the technique, was shown on patients with alcoholism.

Burova E. P. et al. observed an improvement in the psoriatic process when he was combining the illumination of GNL (A = 633 nm, 12 mW, exposure - 10 min) of plaques and affected joints externally with extracorporeal ultraviolet occultation (UFO) every other day[12]. Since then UV lamps are almost entirely replaced by modern and more efficient laser diodes, and self-illumination passes through a special lightguide intravenously, it seems promising to adapt this technique using modern high-performance equipment.

Recently appeared diode lasers with A = 520-525 nm have allowed the development of highly effective physiotherapeutic equipment for external application, and for VLOK. The first clinical studies using green diode lasers for intravenous laser illumination of blood (VLOK-667) have already been published[13].

The purpose of this study was to evaluate the effectiveness of our treatment methodology for patients with psoriasis, including VLOK-667 and local exposure of pulsed infrared LIL.

2. METHODOLOGY

264 patients with common forms of vulgar psoriasis in the stage of progression (163 men and 101 women) aged 24 to 63 years (mean age 47 years) were examined at the university clinic of Saratov Regional Clinical Dermatovenerologic Dispensary. Diagnosted with the disease from 1 year to 30 years ago.

Patients were divided into two groups (table 1): the main group of the study was 134 people, in which combined laser therapy was performed, and a control group of comparison -130 people, in which only standard basic therapy was performed according to the clinical recommendations for the treatment of psoriasis. The average PASI-index for the main group was 24.5 ± 4.9 points before the start of treatment, and 23.4 ± 4.2 points in the comparison groups[14].

Table 1. Distribution of patients with psoriasis by groups

	Main group	**Control group**
Number of patients	134 (82 men and 52 women)	130 (93 men and 37 women)
Age, years	24 - 60 years old	26 - 63 years
Duration of the disease	from 1 year to 30 years	from 1 year to 30 years
The PASI index (M ± a)	24.5 ±4.9	23,4 ±4,2

In the main group laser therapy was included in the complex of therapeutic measures according to the original technique with a laser therapeutic device «Lazmik – VLOK» (Reg). Certificate No. 2014/1410 RZN from 175 06.02.2014) with laser heads radiating. For VLOK, sterile disposable light guides KIVL-01 were used according to TU 9444-005-72085060-2008 from the Research Center «Matrix» (Russia, Moscow).

According to the method proposed by us (table 2), 15 daily sessions were performed according to the following scheme: in 4 symmetrical lesions locally was applied 2 min per zone in contact with laser radiant head ML-635-40 in maximum power with varying frequency; VLOK-667, laser radiating head KL-VLOK-525-20 with varying power and exposure (table 3).

Table 2. Parameters of laser emitting heads to the ALT "Lasmic- VLOK" used in the laser therapy scheme for psoriasis patients

Laser Type	Methodology	Length wave, NM	Number of laser diodes, pcs.	Maximal power	Mode of work	Duration pulse, NS	Maximum frequency, Hz
ML-635-40	Outwardly, NLOK	635	8	40 W	Pulse	100-130	10,000
CL-VLOK-525-20	VLOK	525	1	120 mW	Continuous	-	-

Table 3. Parameters of combined laser therapy of patients with psoriasis

Session	Locally (ML-635-40)	VLOK-525 (CL-VLOK-525)	
	Frequency, Hz	Power, mW	Exposition, mines
1	80	2	5
2	150	5	7th
3	600	5	12
4	500	10	15
5	3000	15	15
6-7	6000	15	20
8-10	10,000	20	20
11-12	1500	20	20
13-15	80	20	20

To assess the quality of the treatment, dermatoscopic examination was performed on psoriatic elements in the video dermatoscope MoleMaxHD (Austria) with x30 and x60 of aumentation[15].

The results of the study were processed statistically using statistical software packages Statistica for Windows and calculation of M ± 5. Differences between the compared groups were considered reliable at p s 0.05.

3. RESULTS

Before treatment, over the entire course of the psoriaticl, elements were clearly visualized dermatoscopically like multiple expressed atypical vessels in the form of commas, rings, foci of peeling, keratotic layers, flakes of yellowish or grayish color (Fig. 1, Fig. 2).

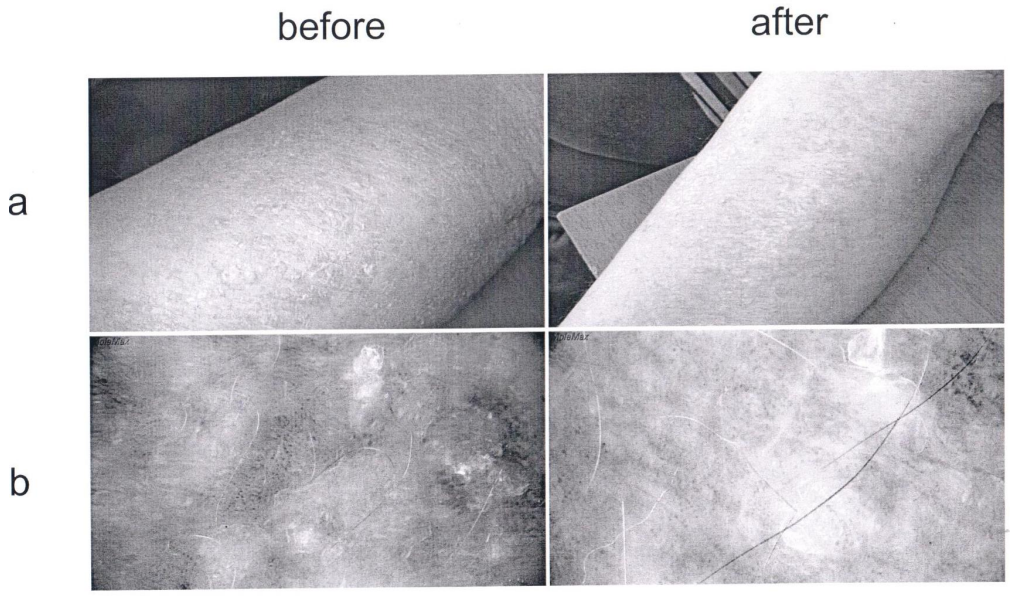

Figure 1. Patient A., 54 years old, before and after combined laser therapy. Diagnosis: Psoriasis vulgaris, a - photo; b - dermatoscopic picture.

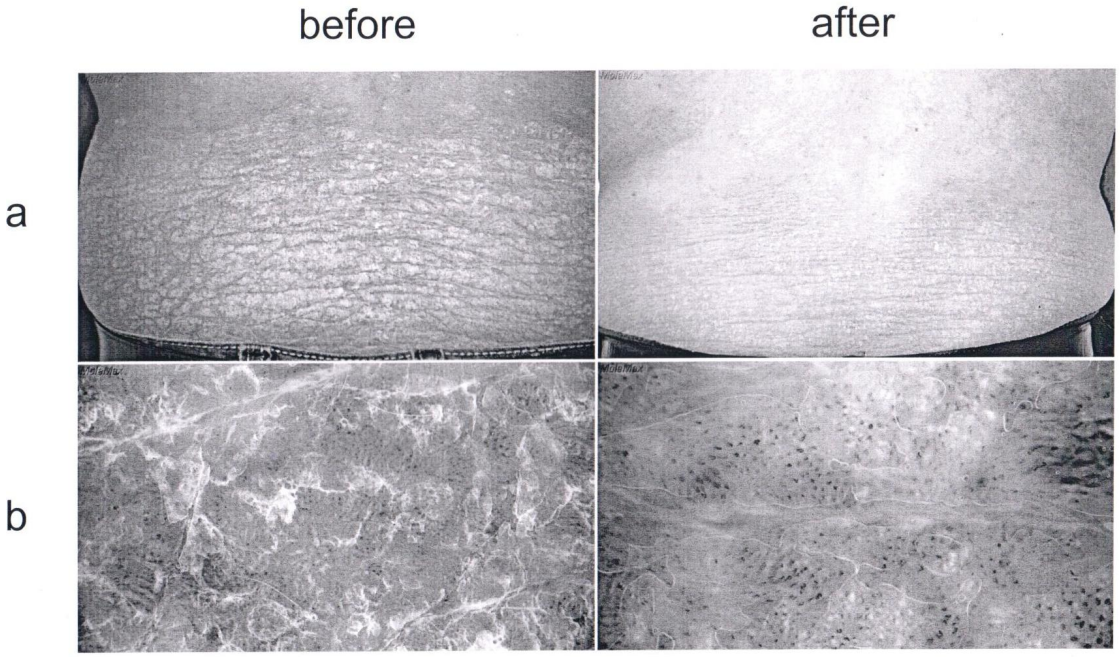

Figure 2. Patient T., 32 years old, before and after combined laser therapy. Diagnosis: Psoriasis vulgaris, a - photo; b - dermatoscopic picture.

On the third day in patients of the main group, and after two sessions of combined laser therapy, there was a marked decrease in erythema and infiltration of the elements in the lesions, they were significantly free of exfoliation. The average PASI-index was 18.62 ± 3.6 (decrease by 24.1% of the baseline level), on the dermatoscope, a significant decrease in the number and severity of the vascular elements of the keratotic layers, scales, was observed throughout thlength of the elements.

On the 7th day, after 5 sessions of combined laser therapy, the erythema of the elements on the skin was moderate, infiltration and flaking significantly decreased. The PASI-index in the main group of patients was 16.8 ± 3 8 (decrease by 31.3%).

On the 10th day, after 8 sessions of combined laser therapy with dermatoscopic examination, a significant decrease in the number and severity of vascular elements was observed, as there were no peeling spots, scales, keratotic layers; clinically papules and plaques were pale pink, infiltration was negligible. The decline in the average PASI-index was 10.7 ±3.1 (a decrease of 56.3%).

After the termination of the course of treatment (15 sessions of laser combination therapy) in the main group all patients except one had regression of the elements on the skin, the average PASI-index was 8.9 ± 3.5 (Fig. 3).

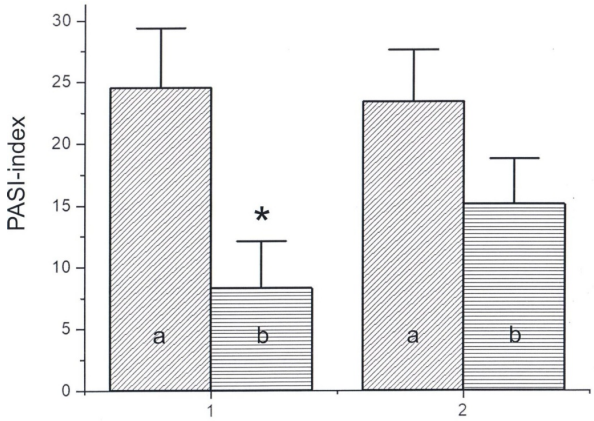

Figure 3. PASI-index before (a) and after (b) treatment in patients who received combined laser therapy (1) and in control group (2). * - p<005.

In the comparison group, the dynamics of recovery was not so obvious. Methotrexate was used in therapy of patients and at the end of treatment the average PASI-index was 14 ± 3 8 (p <0.05).

4. CONCLUSIONS

Thus, combined laser therapy of patients with a moderate form of psoriasis (10 <PASI <40), including a local effect on the psoriatic foci by a pulsed LRI of red spectrum (635 nm) with a power of 40 W with a pulse repetition rate of up to 10 Hz 000- VLOK-667 according to the study can effectively stop inflammatory changes, lead to a decrease in erythema, infiltration and flaking. There is a rapid decrease in the area of the affected skin. In the main treatment group, characterized as a clinical cure, a significant improvement was noted in all 134 patients. In the main group in which combined laser therapy was performed, a manifest effect was observed in all patients without prescription of cytotoxic drugs, and the fastest regression was observed in the first 3 days and after the 10th procedure of laser therapy.

REFERENCES

[1] Dovzhanskij S. I., and Utz S. R., [Psoriasis or psoriatic disease], Izdatel'stvo saratovskogo universiteta, Saratov, 192 (1992).
[2] Moskvin S. V., Utz S. R., and Shnaider D. A., "Combined laser therapy of patients with psoriasis," J. Vestn. novyh medicinskih tehnologij. 4, 99-103 (2015).
[3] Moskvin S. V., Utz S. R., and Shnaider D. A. "Combined laser therapy of psoriasis patients, including intravenous laser blood coverage and local exposure to foci," J. Lazernaja medicina. 4, 44-48 (2015).
[4] Moskvin S. V., and Utz S. R., [Dermatology and cosmetology], In. 'The Fundamentals of Laser Therapy." A series of "Effective Laser Therapy," Triada, Tver 381-433 (2016).
[5] Moskvin S. V., Utz S. R., Shnaider D. A., Gus'kova O. P., and Chernova N.L., "Combined intravenous and local (on

foci) illumination with low-intensity laser light with a wavelength of 525 nm in dermatology, " J. Lazernaja medicina. 3, 88-89 (2016).
[6] Rakcheev A. P., Voloshin. R. N., and Samsonov V. A., "The effectiveness of low-intensity laser radiation and its effect on immune complexes, the kallikrein-kinin system indexes and sialic acids in the treatment of patients with psoriasis," J. Vest. Dermatol., 2, 8-10 (1986).
[7] Filippov N. E. "Laser therapy in the complex treatment of psoriasis, " J. Fizich. Medicina. 54, 1-2 (1994).
[8] Utz S. R, and Volnuhin V. A., [Low-intensity laser therapy in dermatology], Izdatel'stvo saratovskogo universiteta, Saratov, Izdatel'stvo saratovskogo universiteta, Saratov, 93 (1998).
[9] Vil'shonkov A. I., Orlov E. V., and Seleznev E. I., "Treatment of patients with psoriasis by intravascular laser irradiation of blood," J. Vestn. dermatol. and venerol. 1, 36-37 (1997).
[10] Novakovskij A. L., Novakovskaja O. A., and Losickij E. A., "New laser medical technologies in the treatment of a common form of psoriasis", Proceedings of Int. conf. "Laser physics and the use of lasers" Minsc, 52 (2003).
[11] Nedosekova N. G., "Features of the course and therapy of psoriasis burdened, " PhD abstract. Moscow. 15 (1991).
[12] Burova E. P., Pirjazev A. P., and Atanaev T. B., "Low-intensity lasers in complex therapy of psoriasis, " Tez. int. symp. "The use of lasers in surgery and medicine," Moscow. 2, 191-193 (1989)
[13] Perlamutrov Ju. N., Chernova N. I., Ol'hovskaja K. B., and Moskvin S. V., "Combined laser therapy with a reactivated form of cytomegalovirus infection of the urogenital tract in women of reproductive age, " J. Questions of the balneology, physiotherapy and therapeutic physical culture. 3, 45-51 (2013).
[14] Schmitt J., and Wozel G., "The psoriasis area severity index is the adequate criterion to define severity in chronic plaque-type psoriasis," J. Dermatology. 210, 194-199 (2005).
[15] Utz S. R., Sherstobitova K. Ju., and Shnaider D. A., "Diagnostic value of dermatoscopy in psoriasis," Saratov journal of medical scientific research. 3, 462-466 (2015).